




Cite this article as: Van Praet KM, Kofler M, Akansel S, Montagner M, Meyer A, Sündermann SH *et al.* Periareolar endoscopic minimally invasive cardiac surgery: postoperative scar assessment analysis. *Interact CardioVasc Thorac Surg* 2022; doi:10.1093/icvts/ivac200.

Periareolar endoscopic minimally invasive cardiac surgery: postoperative scar assessment analysis

Karel M. Van Praet ^{a,*}, Markus Kofler ^a, Serdar Akansel ^a, Matteo Montagner ^a, Alexander Meyer^{a,b}, Simon H. Sündermann ^{a,c}, Volkmar Falk ^{a,c,d} and Jörg Kempfert^a

^a Department of Cardiothoracic and Vascular Surgery, German Heart Center Berlin, Berlin, Germany

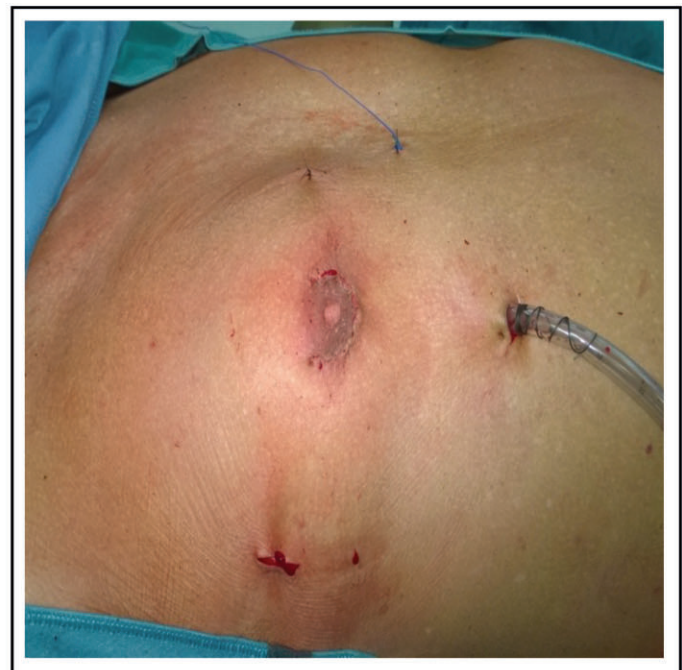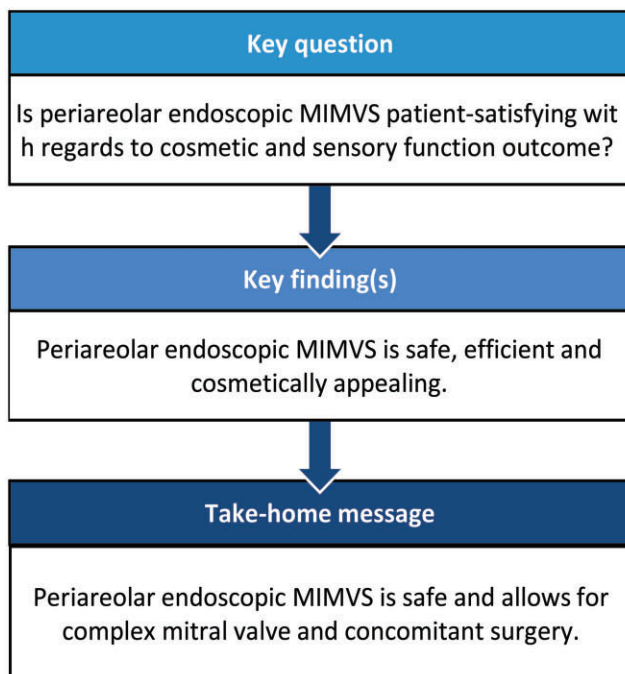
^b Berlin Institute of Health, Berlin, Germany

^c Department of Cardiovascular Surgery, Charité—Universitätsmedizin Berlin, corporate member of Freie Universität Berlin, Humboldt-Universität zu Berlin, and Berlin Institute of Health, Berlin, Germany

^d Translational Cardiovascular Technologies, Institute of Translational Medicine, Department of Health Sciences and Technology, Swiss Federal Institute of Technology (ETH) Zurich, Zurich, Switzerland

* Corresponding author. Department of Cardiothoracic and Vascular Surgery, German Heart Center Berlin, Augustenburger Platz 1, 13353 Berlin, Germany. Tel: +49-30-4593-2227; fax: +49-30-4593-2100; e-mail: vanpraet@dhzb.de; karel.vanpraet@gmail.com (K.M. Van Praet).

Received 18 February 2022; received in revised form 17 July 2022; accepted 20 July 2022



Abstract

OBJECTIVES: The standard approach for minimally invasive cardiac surgery (MICS) for repair of the atrioventricular valves is a right lateral minithoracotomy. In this study, we report our experience with a periareolar endoscopic approach, which aims at an optimal cosmetic outcome while preserving optimal clinical outcomes.

Presented at the 31st Annual Meeting of the European Association for Cardio-Thoracic Surgery, Vienna, Austria, 7–10 October 2017.

METHODS: All patients underwent periareolar endoscopic MICS using high-definition three-dimensional endoscopic visualization without additional rib-spreading. Patients presented with degenerative and/or functional mitral regurgitation. Patients undergoing concomitant tricuspid valve surgery, cryo-ablation, patent foramen ovale closure, left atrial appendage occlusion and/or left atrial myxoma extirpation were included. This descriptive article analysed the aesthetic and functional outcome of the periareolar scar using 5 most common and clinically sound scar assessment scales. For statistical analysis of the scar assessment grading scales, box and whisker plots were calculated depicting median, interquartile range and high and low range data points.

RESULTS: Median scar assessment scale scores for $n = 100$ male patients (response rate 100/109; 91.7%) were 2 [1, 4], 7.5 [6, 9], 11 [8, 14], 3 [2, 3] and 10 [9, 11] for the Vancouver scar scale, Manchester scar scale, patient scar assessment scale, Stony Brook scar evaluation scale and Dermatology Quality of Life Index scale, respectively. Ninety-seven patients received mitral valve repair, 7 mitral valve replacement, whereas 5 had left atrial myxoma extirpation. Concomitant tricuspid annuloplasty, cryo-ablation, left atrial appendage occlusion and patent foramen ovale closure surgery were performed in 12, 29, 5 and 8 patients, respectively. Median procedure, cardiopulmonary bypass and cross-clamp times were 169.5 [154.3, 189.3], 111.5 [97, 127], and 68.5 [58.8, 81] min, respectively.

CONCLUSIONS: Periareolar endoscopic MICS is safe and cosmetically appealing. It is feasible and allows for complex mitral valve repair, mitral valve replacement and concomitant surgery. Data from 5 scar assessment scales suggest that this technique delivers patient-satisfying results regarding functional and cosmetic outcomes.

Keywords: Cardiac surgery • Minimally invasive • Endoscopic • Periareolar approach • Mitral valve

ABBREVIATIONS

3D	Three-dimensional
CPB	Cardiopulmonary bypass
DQLI	Dermatology Quality of Life Index
HD	High-definition
MICS	Minimally invasive cardiac surgery
MIMVR	Minimally invasive mitral valve repair
MIMVS	Minimally invasive mitral valve surgery
MSS	Manchester scar scale
PSAS	Patient scar assessment scale
RLMT	Right lateral mini-thoracotomy
SBSES	Stony Brook scar evaluation scale
VSS	Vancouver scar scale

INTRODUCTION

Minimally invasive mitral valve repair (MIMVR) surgery has evolved as a routine procedure in specialized centres [1]. Patients after MIMVR enjoy earlier return to activity, less wound infections, less trauma and faster recovery [2]. The most widely used MIMVR approach is performed through a right lateral mini-thoracotomy (RLMT) mostly under direct vision with two-dimensional video assistance [3]. More recently, periareolar endoscopic three-dimensional (3D) high-definition (HD) minimally invasive cardiac surgery (MICS) was developed to enable the treatment of the atrioventricular valves through even smaller incisions. This ‘percutaneous’ approach reduces the surgical trauma further [4]. The periareolar approach in minimally invasive mitral valve surgery (MIMVS) consists of a small convex incision that straddles along the right areolar border through which the surgeon gains access to the heart through the 3th, 4th or 5th intercostal space without traumatic rib-spreading [5–9]. With regard to plastic and reconstructive surgery, zigzag transareolar approaches closely approximate the nipple and improve exposure, but scar appearance remains problematic, and there is a risk of ductal injury and capsular contracture. Zelken *et al.* [10] performed 11 augmentation mammoplasties through a transareolar–periareolar incision. They were able to show that nipple sensation was maintained or improved in 100% of patients surveyed, with all patients being satisfied [10]. Transareolar–periareolar scars were well tolerated in

their series and they did not observe infection or sensory disturbances [10].

In this study, we report our experience with the periareolar approach during endoscopic MIMVS as well as report cosmetic and functional outcomes using postoperative scar assessment scales.

PATIENTS AND METHODS

Ethics statement

The corresponding local ethics committee (Charité Medical School, Berlin, Germany) approved the study, which complies with the Declaration of Helsinki (ethical approval number: EA4/090/18). Patient’s informed consent was waived due to the retrospective nature of the study.

Patient population

Between November 2017 and January 2019, we retrospectively analysed our in-house minimally invasive mitral/tricuspid valve surgery database for male patients who underwent periareolar MICS using HD 3D endoscopic visualization without additional rib-spreading. As depicted in Table 1, patients with anterior, posterior and/or bileaflet degenerative mitral valve regurgitation, atrial and/or ventricular functional mitral valve regurgitation and/or left atrium tumour were included in this study. We did not exclude patients receiving concomitant tricuspid valve surgery, redo mitral valve surgery, left atrial appendage occlusion, left atrial cryo-ablation, patent foramen ovale closure, surgery due to atrioventricular valve endocarditis and/or patient presenting with severely calcified valve structures.

Scar assessment scores

We analysed functional, cosmetic and psychological consequences of the periareolar incision. These variables were assessed through a questionnaire including several reliable, consistent, feasible and valid scar assessment scales.

Vancouver scar scale. The Vancouver scar scale (VSS) is the most widely used rating scale for scars [12–14]. Four physical

Table 1: Pathology distribution and procedural data

Variables	Patients operated upon endoscopically via the periareolar RLMT approach (n = 109)
Degenerative MV regurgitation (type II)	93 (85.3%)
AML prolapse	21 (22.6%)
PML prolapse	76 (81.7%)
Bileaflet prolapse	16 (17.2%)
Functional MV regurgitation	9 (8.3%)
Atrial (type I)	5 (55.6%)
Ventricular (type IIIb)	4 (44.4%)
MV infective endocarditis	5 (4.6%)
MV annular calcification	101 (92.7%)
No	2 (1.8%)
Anterior	6 (5.5%)
Posterior	0 (0%)
Anterior + posterior	
Surgery	97 (89%)
MV repair	5 (4.6%)
MV replacement (biological)	2 (1.8%)
MV replacement (mechanical)	5 (4.6%)
Left atrial tumour extirpation	
MV repair (n = 97/109) strategy	75 (77.3%)
PML neochords	17 (17.5%)
AML neochords	37 (38.1%)
Leaflet cleft closure	5 (4.6%)
Isolated ring annuloplasty	2 (2.1%)
Leaflet triangular resection	0 (0%)
Edge-to-edge (Alfieri stitch)	
MV repair rate for when judged 'likely' repairable by a multidisciplinary team ^a	97 (100%)
MV repair (n = 97/109) attempts ^b	93 (95.9%)
One effort	4 (4.1%)
Two efforts	
Mitral annuloplasty model (n = 97/109)	86 (88.7%)
Carpentier-Edwards Physio II ring	3 (3.1%)
LivaNova Memo 3D ring	6 (6.2%)
LivaNova Memo 4D ring	2 (2.1%)
Cosgrove-Edwards band	
Concomitant surgery	54 (49.5%)
Left atrial Cox-maze IV	29 (53.7%)
PFO closure	8 (14.8%)
Tricuspid valve repair	12 (22.2%)
LAA occlusion	5 (9.3%)

Categorical variables are presented as absolute numbers with corresponding percentages.

^aAccording to the example targets for surgical outcomes in repair of MV prolapse published by Chambers *et al.* [11].

^bOne MV repair attempt is defined by 1 mitral repair effort during 1 cross-clamp session.

AML: anterior mitral leaflet; LAA: left atrial appendage; MV: mitral valve; PFO: patent foramen ovale; PML: posterior mitral leaflet; RLMT: right lateral mini-thoracotomy.

The bold refers to the overall amount of patients that presented with "Degenerative MV regurgitation (type II)" or with "Functional MV regurgitation".

characteristics are scored: height, pliability, vascularity and pigmentation, and each variable includes ranked subscales that are summed up to obtain a total score ranging from 0 to 13, with 0 representing normal skin and higher values indicating worse scars [13–15].

Manchester scar scale. The Manchester scar scale (MSS) includes 6 items: contour, texture, colour, distortion, shiny surface and overall patient's opinion [12, 13, 16]. Each of the first

4 parameters is given a score between 1 and 4 [12, 16]. Whether a scar is matte or shiny is recorded (1 and 2 points, respectively), and the patient's overall rating is measured on a 0–10 visual analog scale [12, 16]. The total score is obtained by summing up the 6 items; higher values indicate worse scars [12, 13, 16].

Patient scar assessment scale. The patient scar assessment scale (PSAS) contains 6 items which are scored numerically and ranges from 6–60 points: scar colour, pliability, thickness, relief, itching and pain [12, 13, 17, 18]. Six points represent normal skin and higher values indicate worse scars. The PSAS has been proven to have a good internal consistency [12, 13, 17, 18].

Dermatology Quality of Life Index. The Dermatology Quality of Life Index (DQLI) questionnaire has played an important role in assessing dermatology-specific health-related quality of life and has affected several medical decision-making processes [12, 13, 16, 19]. It is a simple 10-question validated questionnaire and the most frequently used instrument in studies of randomized controlled trials in dermatology and ranges from 9 to 36 points [12, 19]. Nine points represent normal skin and higher values indicate worse scars.

Stony Brook scar evaluation scale. The scars are assigned 0–1 point for the presence or absence of the following: a width greater than 2 mm at any point of the scar, a raised (or depressed) scar, a darker colouration than surrounding skin, any hatch or staple marks, an overall poor appearance [12, 13, 16]. The Stony Brook scar evaluation scale (SBSSES) measures overall cosmetic appearance and ranges from 0 to 5 points [12, 13, 16]; higher values indicating better scars.

Surgical technique

All patients underwent periareolar MICS using HD 3D endoscopic visualization without additional rib-spreading, the details of which have been previously described in the literature [1–3, 21, 22]. The periareolar approach for MICS in male patients entailed a 3-cm small convex incision that straddled the right areolar border (~50% of the inferior or lateral areolar circumference) [21] (Fig. 1). It was important that the outlines or contour of the right aureola were large enough; therefore, obesity was a relative contra-indication and patients with a BMI of ≥ 25 kg/m² were not promptly excluded from this technique. The patient was connected to cardiopulmonary bypass (CPB) by peripheral cannulation of the femoral artery and vein. The Endoreturn arterial cannula (21 or 23FR) was typically used for arterial perfusion but if the size of the arterial cannula was rather small, a higher arterial line pressure should have been expected [4]. During peripheral retrograde arterial perfusion, the CPB arterial line pressure behind the oxygenator should not have exceeded 400 mmHg. If this would have been the case, an additional arterial perfusion cannula should have been placed on the contralateral side.

Mitral valve repair for degenerative mitral valve regurgitation was most commonly performed utilizing the Goretex neochordae 'Loop technique' [23]. An annuloplasty ring was implanted to support the repair (Fig. 2). Mitral valve competency was restored in patients with Barlow's disease or bileaflet disease utilizing a different techniques from leaflet resection to leaflet preserving techniques mainly using neochordae.

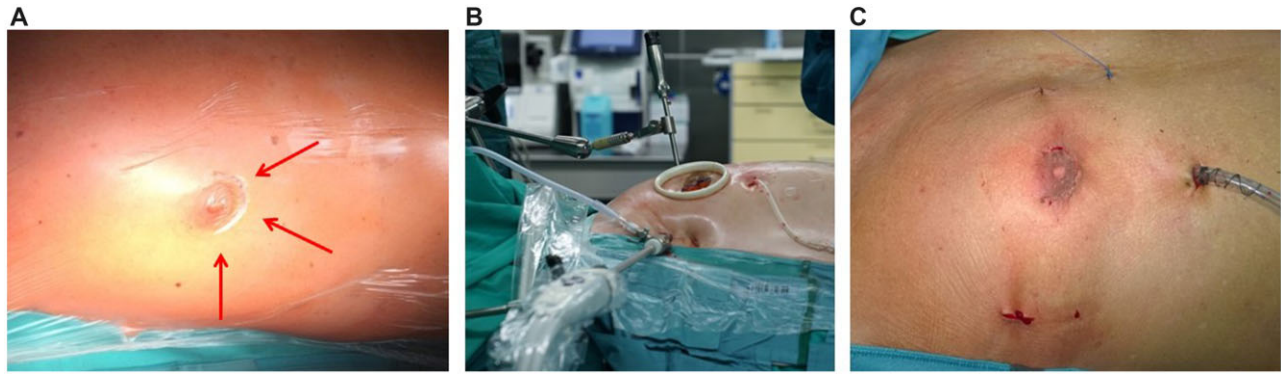


Figure 1: The periareolar incision during endoscopic minimally invasive cardiac surgery throughout the procedure. The minimally invasive periareolar approach during minimally invasive cardiac surgery in male patients entails a 3cm small convex incision that straddles the right areolar border. **(A)** Incised periareolar skin. **(B)** Periareolar right lateral mini-thoracotomy high-definition three-dimensional endoscopic minimally invasive cardiac surgery; a soft-tissue retractor through the right lateral mini-thoracotomy enhances the surgical working port. **(C)** Aesthetically appealing postoperative result.

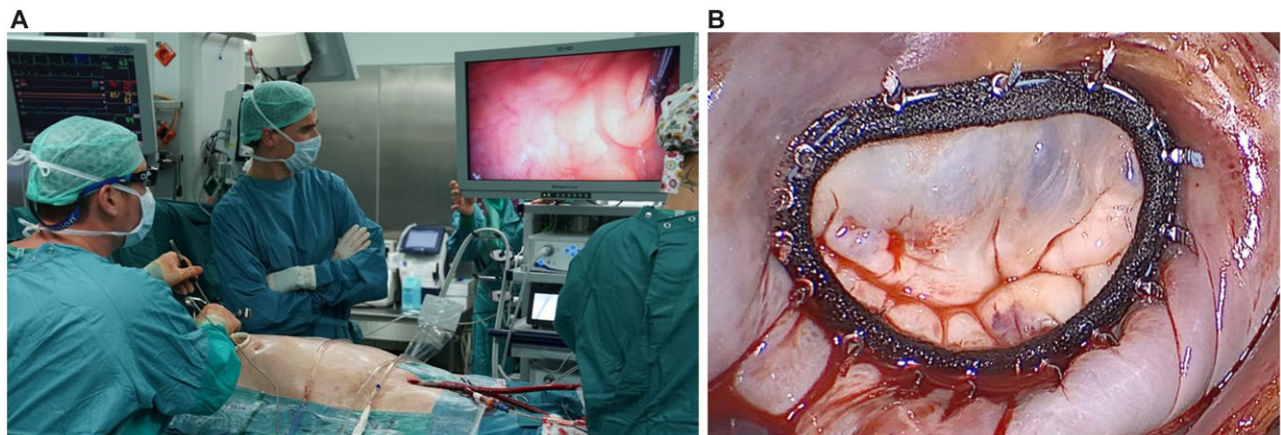


Figure 2: Setup: periareolar endoscopic high-definition three-dimensional minimally invasive mitral valve surgery. **(A)** The surgeon operating on the mitral valve endoscopically with 3D glasses. Peripheral cardiopulmonary bypass with endoaortic balloon occlusion clamping. **(B)** Periprocedural result after mitral valve repair (annuloplasty + pre-measured loops to the free edge of the posterior mitral leaflet).

Statistical analysis

Categorical variables are presented as absolute numbers with corresponding percentages. The Shapiro-Wilk test was used to test for normal distribution of the variables. Normal distributed continuous variables are presented as mean with standard deviation. Not normal distributed continuous variables are presented as median with interquartile range [25th percentile, 75th percentile]. The manuscript is limited to descriptive statistics without group comparisons. The statistical analyses were performed with SPSS® from IBM® Version 27.

RESULTS

One hundred and nine male patients (median age 58.5 years [48 years, 68 years]) underwent periareolar RLMT HD 3D endoscopic MICS using the endo-aortic balloon occlusion technique. Detailed baseline characteristics are reported in Table 2. Regarding the cannulation technique for CPB, most patients were cannulated utilizing the peripheral surgical open cut-down technique [99 patients (90.8%) vs 10 patients who were cannulated using the percutaneous approach (9.2%)]. More than 80% of the patients received Custodiol for cardioplegic arrest and the calculated median aortic cross-clamp time was 68.5 min [58.8 min, 81 min]. Further

details regarding intraoperative outcome are illustrated in Table 3. The median VSS score was 2 [1, 4], whereas the median patient scar assessment score was 11 [8, 14]. Median MSS, SBSES and DQLI were 7.5 [6, 9], 3 [2, 3] and 10 [9, 11], respectively. The scars were assessed at an average of 4.9 months after the operation (range, 2–15 months; median, 9 months). The response rate was 100/109 (91.7%). More details concerning the postoperative scars are shown in Table 4. Figure 3 depicts the distribution of the 5 scar assessment scale scores by ways of box plots. There were no perioperative strokes (0%) and no myocardial infarctions (0%). Five patients (4.6%) were taken back to the operating room and needed surgical revision due to bleeding. Median left ventricular function was good (55% [50%, 60%]) upon discharge from the hospital and only 1 patient (0.9%) required perioperative pacemaker implantation. More than 98% ($n = 107$) of patients left the hospital with no/trace mitral regurgitation. Thirty-day mortality rate was 0%. More details about the postoperative outcomes are depicted in Table 5.

DISCUSSION

The periareolar approach was developed to further reduce the trauma of endoscopic MICS [5–8, 24, 25]. This approach, which has been used for decades in aesthetic and/or reconstructive

Table 2: Baseline characteristics of the patient population

Variables	Patients operated upon endoscopically via the periareolar RLMT approach (n = 109)
Age (years)	58.5 [48, 68]
Male sex	109 (100%)
Log. EuroSCORE I	2.32 [1.51, 4.79]
EuroSCORE II	0.67 [0.56, 0.95]
MV STS PROM	0.52 [0.28, 0.8]
Body mass index (kg/m ²)	25 [23.2, 27.5]
Body surface area (m ²)	2.02 (± 0.2)
Chronic lung disease ^a	
No	99 (90.8%)
Mild	2 (1.8%)
Moderate	5 (4.6%)
Severe	3 (2.8%)
Chronic kidney disease ^b	8 (7.3%)
Preop NYHA classification	
I	34 (31.2%)
II	54 (49.5%)
III	21 (19.3%)
IV	0 (0%)
Preop LVEF (%)	60 [55, 65]
Preop RVEF (%)	60 [58, 62]
Left atrial tumour	5 (4.6%)
Previous cardiac surgery	
SAVR	1 (0.9%)
CABG	3 (2.8%)
MV clipping (TEER)	1 (0.9%)
MV replacement	0 (0%)
MV repair	5 (4.6%)
Mitral regurgitation	
No/trace	5 (4.6%)
Mild	1 (0.9%)
Moderate	20 (18.3%)
Severe	83 (76.1%)
Mitral stenosis	
No/trace	102 (93.6%)
Mild	0 (0%)
Moderate	1 (0.9%)
Severe	6 (5.5%)
Tricuspid regurgitation	
No/trace	73 (67%)
Mild	24 (22%)
Moderate	9 (8.3%)
Severe	3 (2.8%)
Atrial fibrillation	
Paroxysmal	14 (12.8%)
Persistent	13 (11.9%)
Permanent	4 (3.7%)

Categorical variables are presented as absolute numbers with corresponding percentages. Normal distributed continuous variables are presented as mean ± standard deviation. Not normal distributed continuous variables are presented as median with interquartile range [25th percentile, 75th percentile].

^aChronic lung disease is defined according to the STS Risk Calculator definition (<https://riskcalc.sts.org/stswebriskcalc/calculate>).

^bChronic kidney disease is defined as ≥ moderately impaired renal function (50–85 ml/min).

CABG: coronary artery bypass grafting; LVEF: left ventricular ejection fraction; MV: mitral valve; NYHA: New York Heart Association; MV STS PROM: mitral valve Society of Thoracic Surgeons-predicted risk of mortality; RLMT: right lateral mini-thoracotomy; RVEF: right ventricular ejection fraction; SAVR: surgical aortic valve replacement; TEER: transcatheter edge-to-edge repair.

surgery, showed low rates of complications with excellent aesthetic outcomes [10, 26].

Periareolar MIMVS is currently our approach of choice especially for male patients with a large enough periareolar border

Table 3: Intraoperative outcome

Variables	Patients operated upon endoscopically via the periareolar RLMT approach (n = 109)
Peripheral cannulation	
Surgical open cut-down	99 (90.8%)
Percutaneously	10 (9.2%)
Cross-clamping method	
Endoaortic balloon occlusion	109 (100%)
Transthoracic external clamp	0 (0%)
Fibrillating heart	0 (0%)
Cardioplegia	
Custodiol	91 (83.5%)
Del Nido	18 (16.5%)
Overall procedure time (min)	169.5 [154.3, 189.3]
CPB time (min)	111.5 [97, 127]
Cross-clamp time (min)	68.5 [58.8, 81]

Categorical variables are presented as absolute numbers with corresponding percentages. Normal distributed continuous variables are presented as mean ± standard deviation. Not normal distributed continuous variables are presented as median with interquartile range [25th percentile, 75th percentile].

CPB: cardiopulmonary bypass; ; RLMT: right lateral mini-thoracotomy .

(right nipple) who presents with (complex) mitral valve disease and/or additional cardiac pathologies. Despite the microinvasive incision, both valve replacement and valve repair and concomitant procedures can be accomplished.

Figure 3 and Table 4 suggest satisfying aesthetic and functional outcome after scar validation by the patients postoperatively. The PSAS has 6 domains: all domains are graded by the patient on a 10-point scale; 1 indicates the best or most normal result and 10 indicates the worst or most disfiguring result [27]. A summary score of 6 corresponds to normal skin, and 60 is the worst scar imaginable to the patient [27]. As shown in Fig. 1 and Table 4, the median PSAS score in our group was 11 [8, 14], indicating that the periareolar scar was being perceived by the patients as near to normal skin. Utilizing the PSAS and VSS scar assessment scales, ÓConnell *et al.* [27] showed in their comparative study (conventional access parathyroidectomy versus minimal access parathyroidectomy) that >90% of their patients assessed believed their scar cosmesis to be excellent or good (median PSAS 9 [6, 15]; median VSS 2 [1, 5]). We believe that this report can be used as a benchmark for good cosmetic outcome concerning PSAS and VSS scar assessment scales. In our cohort, median VSS (2 [1, 4]) (Table 4) was found to be the same value as in their report, which leads to our conclusion suggesting that our patients were satisfied with the periareolar cosmetic result. Moreover, the MSS, which is a validated tool and has been used in other studies to assess scar aesthetics [28], has been shown to have a high correlation with histology and a good inter-rater reliability [16]. Yang *et al.* [28] analysed scarring cosmesis of a surgical wound by using the MSS tool at the third month after supraclavicular thyroidectomy. At the 3rd month after surgery, they found high satisfaction levels utilizing validated Patient Satisfaction Assessment Forms and an MSS score that ranged between 5 and 7 [28]. The postoperative findings concerning the MSS in our cohort (median 7.5 [6, 9]) are in line with their data and suggest perception of good cosmetic results and overall patient satisfaction. Furthermore, in a retrospective comparative

case-control study of patients with facial lacerations who underwent post-surgical closure scar management, Suh *et al.* [29] measured median SBSES scores of 3.1 at 3 months and 3.7 at 6 months for the standard group and 2.37 at 3 months and 3.95 at 6 months for the multimodality group ($P=0.007$). The multimodality (i.e. botulinum toxin, CO₂ fractional laser, triamcinolone and scar revisions were performed within 6 months) group outperformed the standard (i.e. no further wound/scar management) group with respect to PSAS and VSS scores, while the SBSES and visual analog scale increased, indicating an overall scar improvement over time and patient contentment [29]. These reported data are pursuant to our scar assessment scale score values (e.g. median SBSES 3 [2, 3] at an average of 4.9 months after the periareolar MIMVR operation).

The above-mentioned scar assessment scales (PSAS, VSS, MSS and SBSES) mainly assess postoperative scar morphology and appearance (e.g. pigmentation, pliability, vascularity, height, colouration, width and texture). In contrast, the DQLI analyses psychological effects and how the scar affects patients' lives. As

stated by Draaijers *et al.* [18], lower classification numbers are associated with better scar cosmesis, and therefore, we believe that our cohort with a median DQLI of 10 [9, 11] (DQLI score range 9–36) experienced a mild psychological impact. Yet, Finlay and Khan [30] completed the DQLI questionnaire on 100 healthy volunteers (no scarring) and showed a low mean score (1.6, SD 3.5).

Nevertheless, in regard to the SBSES, PSAS and DQLI outlier, as shown in Fig. 3, 1 patient seemed not satisfied with the cosmetic result of his postsurgical scar—this was due to the fact that the scar was raised, itching and painful. We recommended surgical correction and referred our patient to an outpatient aesthetic surgical department.

On the other hand, clinical scar assessments are subjective and the patient's own view of the scar may be very influential in determining the patient's quality of life, irrespective of the actual physical characteristics of the scar. Therefore, we used 5 different scar assessment scales to produce a thorough scar assessment of the periareolar scar. Standardized, verified and certified translated questionnaires were used. The scar assessment scales score show that patients are satisfied with the aesthetic component of the scar and its functional outcome. The latter is attributable to minimal surgical trauma and the absence of rib-spreading.

In 4.6% of cases, a reoperation for bleeding was necessary due to inadequate coagulation and, in 2 cases, for arterial bleeding from the intercostal muscles. Due to the use of a soft-tissue retractor to enhance the periareolar mini-thoracotomy access, smaller intercostal muscle arteries are compressed during surgery. After termination of the operation and mostly when the patient is fully warmed to a normal body temperature, these small arteries vasodilate and may start bleeding incessantly. All re-thoracotomies for bleeding were managed via the original periareolar access site. One patient was taken back to the operating theatre on postoperative day 4 for redo mitral valve repair (posterior leaflet repair), since echocardiography showed residual moderate mitral valve regurgitation.

Table 4: Scar assessment scale scores for $n = 100/109$ (91.7%) patients

Variable	Patients operated upon endoscopically via the periareolar RLMT approach	Score range per scar assessment scale
VSS	2 [1, 4]	0–13
MSS	7.5 [6, 9]	5–16
PSAS	11 [8, 14]	6–60
SBSES	3 [2, 3]	0–5
DQLI	10 [9, 11]	9–36

The questionnaires were sent to the patients' home and, thus, the scars assessed at an average of 4.9 months after the operation (range, 2–15 months; median, 9 months). The response rate was 100/109 (91.7%). Variables are depicted as median with interquartile range [25th percentile, 75th percentile].

DQLI: Dermatology Quality of Life Index; MSS: Manchester scar scale; PSAS: patient scar assessment scale; RLMT: right lateral mini-thoracotomy; SBSES: Stony Brook scar evaluation scale; VSS: Vancouver scar scale.

Limitations

This descriptive study draws data from a single institution, lacks a control group and is not comparative. All patients were operated by 1 surgeon. The study was retrospective in design and comprises a male population only. Hence, the results cannot be

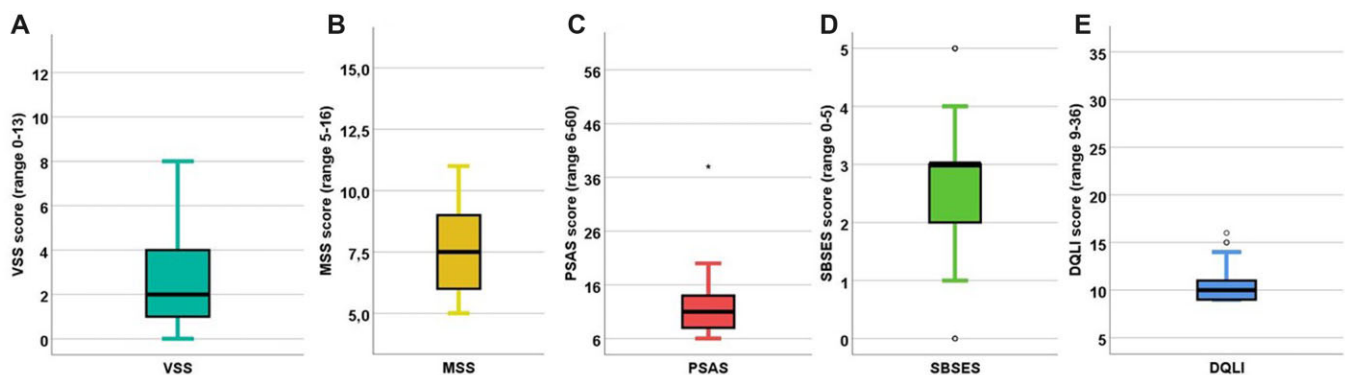


Figure 3: Distribution of scar assessment scale scores. Box plots demonstrating the grading system and spread of 5 scar assessment scale scores depicted as ordinal variables. (A) The Vancouver scar scale total score ranges from 0 to 13, with 0 representing normal skin and higher values indicating worse scars. (B) The Manchester scar scale ranges from 5 to 16; higher values indicate worse scars. (C) The patient scar assessment scale contains 6 items which are scored numerically and ranges from 6 to 60 points: 6 points represent normal skin and higher values indicate worse scars. (D) The Stony Brook scar evaluation scale measures overall cosmetic appearance and ranges from 0 to 5 points, higher values indicating better scars. (E) The Dermatology Quality of Life Index is a simple 10-question validated questionnaire in dermatology and ranges from 9 to 36 points. Nine points represent normal skin and higher values indicate worse scars.

Table 5: Postoperative outcome

Variable	Patients operated upon endoscopically via the periareolar RLMT approach (n = 109)
Mechanical ventilation time (min)	491.5 [373, 755]
ICU stay (h)	24 [24, 48]
Reversion for bleeding	5 (\pm 4.6)
Readmission to the ICU	2 (1.8%)
(Broncho)pneumonia	1 (0.9%)
Low cardiac output syndrome	1 (0.9%)
Surgical revision of the primary MV repair	1 (0.9%)
RBC transfusion	12 (11%)
Platelet transfusion	7 (6.4%)
Stroke	0 (0%)
Mediastinitis	0 (0%)
Myocardial infarction	0 (0%)
Renal insufficiency ^a	2 (1.8%)
New-onset atrial fibrillation during hospital stay	9 (8.3%)
LVEF at discharge (%)	55 [50, 60]
Perioperative pacemaker implantation	1 (0.9%)
MV regurgitation at discharge	
No/trace	107 (98.2%)
Mild	2 (1.8%)
Moderate	0 (0%)
Severe	0 (0%)
30-Day mortality	0 (0%)

Categorical variables are presented as absolute numbers with corresponding percentages. Normal distributed continuous variables are presented as mean \pm standard deviation. Not normal distributed continuous variables are presented as median with interquartile range [25th percentile, 75th percentile].

ICU: intensive care unit; LVEF: left ventricular ejection fraction; MV: mitral valve; RBC: red blood cell; RLMT: right lateral mini-thoracotomy.

^aRenal insufficiency is defined as \geq moderately impaired renal function (50–85 ml/min).

extrapolated to the general population. Problems in the assessment of scars are also known because a patient's own view of a scar is very subjective. There are problems with validity and reliability of scar assessment tools; therefore, more reliable and accurate methods for measuring quantitative aspects of scars are needed. We tried to mitigate this problem by using 5 different scar assessment scales to produce a relative heterogeneous and differentiated scar assessment outcome.

CONCLUSION

In conclusion, periareolar RLMT HD 3D endoscopic MICS using the endo-aortic balloon occlusion technique has shown to be safe, efficient and cosmetically appealing. A repair rate of 99% demonstrates that the technique is safe and reproducible and that it even allows for complex/bileaflet mitral valve repair as well as concomitant procedures. Scores from 5 different scar assessment scales suggest that the periareolar approach delivers patient-satisfying results.

Conflict of interest: none declared.

Data availability

All relevant data are within the manuscript and its supporting information files.

Author contributions

Karel M. Van Praet: Conceptualization; Data curation; Formal analysis; Funding acquisition; Investigation; Methodology; Project administration; Resources; Software; Supervision; Validation; Visualization; Writing—original draft; Writing—review & editing. **Markus Kofler:** Data curation; Formal analysis; Methodology; Supervision; Validation; Visualization; Writing—review & editing. **Serdar Akansel:** Data curation; Writing—review & editing. **Matteo Montagner:** Data curation; Writing—review & editing. **Alexander Meyer:** Data curation; Methodology; Writing—review & editing. **Simon H. Sündermann:** Data curation; Writing—review & editing. **Volkmar Falk:** Supervision; Writing—review & editing. **Jörg Kempfert:** Conceptualization; Data curation; Formal analysis; Funding acquisition; Investigation; Methodology; Project administration; Resources; Software; Supervision; Validation; Visualization; Writing—original draft; Writing—review & editing.

Reviewer information

Interactive CardioVascular and Thoracic Surgery thanks Thierry Bove, Evaldas Girdauskas, Shekar L.C. Reddy and the other, anonymous reviewer(s) for their contribution to the peer review process of this article.

REFERENCES

- Van Praet KM, Kempfert J, Jacobs S, Stamm C, Akansel S, Kofler M *et al.* Mitral valve surgery: current status and future prospects of the minimally invasive approach. *Expert Rev Med Devices* 2021;18:245–60.
- Van Praet KM, Stamm C, Sündermann SH, Meyer A, Unbehaun A, Montagner M *et al.* Minimally invasive cardiac surgery removal of an interatrial intraseptal bronchogenic cyst through a periareolar approach. *Innovations (Phila)* 2018;13:230–2.
- Van Praet KM, Kofler M, Sündermann SH, Montagner M, Heck R, Starck C *et al.* Minimally invasive approach for infective mitral valve endocarditis. *Ann Cardiothorac Surg* 2019;8:702–4. <https://doi.org/10.21037/acs.2019.07.01>.
- Van Praet KM, Stamm C, Sündermann SH, Meyer A, Unbehaun A, Montagner M *et al.*; German Heart Center Berlin, Germany. Minimally invasive surgical mitral valve repair: state of the art review. *Interv Cardiol Rev* 2017;13:14–9.
- Poffo R, Pope RB, Selbach RA, Mokross CA, Fukuti F, da Silva Júnior I *et al.* Video-assisted cardiac surgery: results from a pioneer project in Brazil. *Rev Bras Cir Cardiovasc* 2009;24:318–26.
- Poffo R, Pope RB, Toschi AP, Mokross CA. Video-assisted minimally invasive mitral valve repair: periareolar approach. *Rev Bras Cir Cardiovasc* 2009;24:425–7.
- Suwalski P, Smoczyński R, Kowalewski M, Witkowska A, Drobinski D, Sarnowski W *et al.* A propensity score-adjusted comparison of thoracoscopic periareolar and video-assisted approaches for minimally invasive mitral valve surgery. *Kardiol Pol* 2020;78:1029–31.
- Maruszewski M, Smoczyński R, Kowalewski M, Bartczak M, Witkowska A, Staromyński J *et al.* Pilot study of totally thoracoscopic periareolar approach for minimally invasive mitral valve surgery. Towards even less invasive? *Wideochir Inne Tech Maloinwazyjne* 2019;14:326–32.
- Van Praet KM, Kofler M, Montagner M, Heck R, Eggert-Doktor D, Stamm C *et al.* Minimally invasive mitral valve repair using external clamping—pearls and pitfalls. *J Vis Surg* 2020;6:45.
- Zelken J, Huang J, Wu C, Lin Y, Cheng M. The transareolar-periareolar approach. *Plast Reconstr Surg Glob Open* 2016;74:e1020.
- Chambers JB, Prendergast B, Lung B, Rosenhek R, Zamorano JL, Piérard LA *et al.* Standards defining a Heart Valve Centre: ESC Working Group on Valvular Heart Disease and European Association for Cardiothoracic Surgery Viewpoint. *Eur Heart J* 2017;38:2177–83. <https://doi.org/10.1093/eurheartj/ehx370>.
- Roques C, Téot L. Reviews: a critical analysis of measurements used to assess and manage scars. *Int J Low Extrem Wounds* 2007;6:249–53.
- Vercelli S, Ferriero G, Sartorio F, Stissi V, Franchignoni F. How to assess postsurgical scars: a review of outcome measures. *Disabil Rehabil* 2009;31:2055–63.
- Nedelec B, Shankowsky HA, Tredget EE. Rating the resolving hypertrophic scar: comparison of the Vancouver scar scale and scar volume. *J Burn Care Rehabil* 2000;21:205–12.

- [15] Baryza MJ, Baryza GA. The vancouver scar scale: an administration tool and its interrater reliability. *J Burn Care Rehabil* 1995;16:535–8.
- [16] Vercelli S, Ferriero G, Sartorio F, Cisari C, Bravini E. Clinimetric properties and clinical utility in rehabilitation of postsurgical scar rating scales: a systematic review. *Int J Rehabil Res* 2015;38:279–86.
- [17] Truong PT, Lee JC, Soer B, Gaul CA, Olivotto IA. Reliability and validity testing of the patient and observer scar assessment scale in evaluating linear scars after breast cancer surgery. *Plast Reconstr Surg* 2007;119:487–94.
- [18] Draaijers LJ, Tempelman FRH, Botman YAM, Tuinebreijer WE, Middelkoop E, Kreis RW *et al.* The Patient and Observer Scar Assessment Scale: a reliable and feasible tool for scar evaluation. *Plast Reconstr Surg* 2004;113:1960–5.
- [19] Beausang E, Floyd H, Dunn KW, Orton CI, Ferguson MWJ. A new quantitative scale for clinical scar assessment. *Plast Reconstr Surg* 1998;102:1954–61.
- [20] Akansel S, Suendermann SH, Kofler M, Van Praet KM, Kukucka M, Falk V *et al.* A successful minimally invasive mitral valve repair following delayed device embolization in a patient with Pascal device implantation. *Turk Gogus Kalp Damar Cerrahisi Derg* 2019;28:404–6.
- [21] Van Praet KM, Kofler M, Jacobs S, Falk V, Unbehaun A, Kempfert J. The MANTA vascular closure device for percutaneous femoral vessel cannulation in minimally invasive surgical mitral valve repair. *Innovations (Phila)* 2020;15:568–71.
- [22] Van Praet KM, Nersesian G, Montagner M, Akansel S, Eggert-Doktor D, Kofler M *et al.* Endoaortic balloon occlusion in minimally invasive mitral valve surgery. *Multimed Man Cardiothorac Surg* 2022. <https://doi.org/10.1510/mmcts.2022.017>.
- [23] von Oppell U, Mohr F. Chordal replacement for both minimally invasive and conventional mitral valve surgery using premeasured Gore-Tex loops. *Ann Thorac Surg* 2000;70:2166–8.
- [24] Durdu MS, Baran Ç, Gümüş F, Deniz G, Çakıcı M, Özçınar E *et al.* Comparison of minimally invasive cardiac surgery incisions: periareolar approach in female patients. *Anatol J Cardiol* 2018;20:283–8.
- [25] Zheng XX, Wang ZY, Ma LY, Liu Hong, Liu Huan, Qin J *et al.* Triport periareolar thoracoscopic surgery versus right minithoracotomy for repairing atrial septal defect in adults. *Interact CardioVasc Thorac Surg* 2021;32:313–8.
- [26] Kong X, Chen X, Jiang L, Ma T, Han B, Yang Q. Periareolar incision for the management of benign breast tumors. *Oncol Lett* 2016;12:3259–63.
- [27] O'Connell DA, Diamond C, Seikaly H, Harris JR. Objective and subjective scar aesthetics in minimal access vs conventional access parathyroidectomy and thyroidectomy surgical procedures: a paired cohort study. *Arch Otolaryngol Head Neck Surg* 2008;134:85–93.
- [28] Yang Y-L, Xiang Y-Y, Jin L-P, Pan Y-F, Zhou S-M, Zhang X-H *et al.* Closure of skin incision after thyroidectomy through a supraclavicular approach: a comparison between tissue adhesive and staples. *Scand J Surg* 2013;102:234–40.
- [29] Suh JM, Park SH, Lee JW, Lee SJ, Suh IS, Lee JW *et al.* Clinical outcomes following the early application of multimodal scar programs for facial incisional wounds. *Aesthetic Plast Surg* 2021;45:1772–82.
- [30] Finlay A, Khan G. Dermatology Life Quality Index (DLQI)—a simple practical measure for routine clinical use. *Clin Exp Dermatol* 1994;19:210–6.